



Case Report

Type II A sacralisation: A case report

Khushi Gupta^{1*}, Shalini Choudhary¹, Arvinder Pal Singh Batra¹

¹Dept. of Anatomy, Bhagat Phool Singh Government Medical College, Khanpur Kalan, Sonipat, Haryana, India

Abstract

Lumbosacral transitional vertebrae are anomalies arising in the vertebral column where there is a transition or change from the lumbar vertebra to the sacrum. They usually affect the fifth lumbar or first sacral vertebrae. Castellvi et al. first described a radiographic classification system for these vertebrae, grouping them into seven main types. Sacralization runs in families and varies across races. Its prevalence can range from 4% to 35.9%. Bertolotti correlated it with its clinical significance. The present case report features one such rare vertebra. The significance of this lumbosacral transitional vertebra is that it can lead to degenerative spondylolisthesis, disc herniation, low back pain, spinal or radicular pain, difficulty during labour in females and can complicate orthopaedic procedures. Its knowledge is important for both diagnosis and surgery.

Keywords: Lumbar, Vertebra, Unilateral, Sacrum, Transitional.

Received: 18-03-2026; **Accepted:** 07-04-2026; **Available Online:** 20-04-2026

This is an Open Access (OA) journal, and articles are distributed under the terms of the [Creative Commons Attribution-NonCommercial-ShareAlike 4.0 License](https://creativecommons.org/licenses/by-nc-sa/4.0/), which allows others to remix, tweak, and build upon the work non-commercially, as long as appropriate credit is given and the new creations are licensed under the identical terms.

For reprints contact: reprint@ipinnovative.com

1. Introduction

Lumbosacral transitional vertebrae (L.S.T.V.) are anomalies arising in the vertebral column where there is a transition from the lumbar vertebra to the sacrum. If the lumbar fifth resembles or fuses with the sacrum, it is called sacralization, and if the sacral first resembles or fuses with the lumbar vertebra, then it is called lumbarization.

Sacralization is more common than lumbarization, with a 2:1 ratio.¹ Sacralization can be unilateral or bilateral. Bilateral sacralization is more common than unilateral sacralization.² Embryologically, each vertebra is formed from the fusion of the sclerotome of either side. Lumbarisation and sacralisation occur when there are caudal and cranial shifts.³

Castellvi et al. described a radiographic classification system that identified the seven main types of L.S.T.V.s based on morphological characteristics. In the classification, the transverse process of the sacralised side should be at least 19 millimetres in size. In IA, the transverse process is merely large in size. In type IIA, the transverse process forms a joint

with the sacral ala. In type IIIA, the transverse process is fused with the sacral ala. Type As are unilateral, while Type Bs are bilateral. In type IV, one transverse process is fused and the other is forming a joint with the sacral ala.⁴ (**Figure 1**)

The case observed here is of a unique phenotype. A unilaterally sacralised vertebra that is not fused with the sacrum.

2. Case Report

In this study, a unilaterally sacralised fifth lumbar vertebra, with its left transverse process resembling the sacral ala, was assessed.

The vertebra was represented by the superior lumbar articular processes, which were almost the same distance apart as the inferior processes. It followed Fawcett's rule and represented a horizontal rectangle as seen from the dorsal aspect. Also, the anterior surface of the body was larger and deeper than the posterior surface. The spine was short, rounded and down-turned.

Corresponding author: Khushi Gupta
Email: khudkhushi@gmail.com

<http://doi.org/10.18231/j.ijcap.16409.1775631605>

© 2026 The Author(s), Published by Innovative Publications.

The transverse process on the sacralised side, measured (width x length x height), was 30.5 x 32.2 x 22.9 millimetres. The ala had an irregular inferior surface. It was unilateral and had no bony union with the ala of the sacrum; therefore, as per the classification of Castellvi, it is of type IIA. The vertebral foramen was triangular and showed no stenosis. (Figure 2)

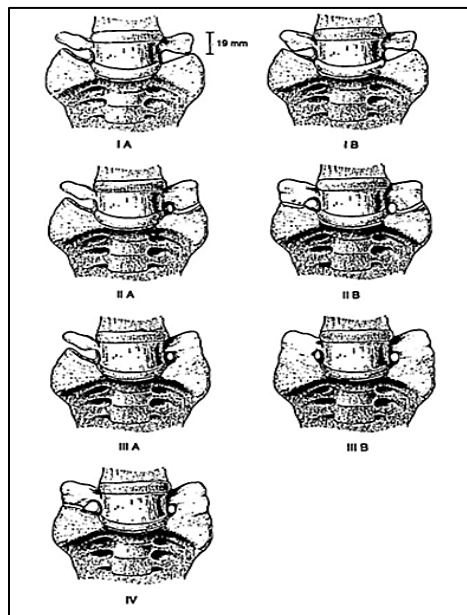


Figure 1: Castellvi's classification of Lumbosacral transitional vertebrae.




Figure 2: Sacralised lumbar vertebra. (A) Superior and (B) Inferior surfaces.

3. Discussion

Sacralisation is known to run in families and varies across races. Its incidence in the Chinese population is 4%, in the British population 8.1%, in Arabs 10%, in Indians in general 16%, in central India 14%, in Australian aboriginals 18%, and in the Turkish population as high as 35.9%.⁵⁻¹⁰

Bertolotti was the first to report the clinical significance of sacralisation, in which the transverse process of the fifth lumbar vertebra is large and fused with the sacrum, ilium, or both, a condition called "Bertolotti syndrome".¹¹ The significance of this lumbosacral transitional vertebra is that it can lead to degenerative spondylolisthesis, disc herniation, spinal or radicular pain, difficulty during labour in females, can complicate orthopaedic and can lead to difficult localisation during anaesthetic procedures. It can also cause

a high incidence of chronic lower back pain, stiffness and reduced mobility in the population.¹²

4. Conclusion

Thus, knowledge of a sacralised vertebra is important for diagnosis and surgery. It can be visualised on x-ray examination and higher investigations, and should always be kept in mind, as "the eyes can only see what the mind knows."

5. Source of Funding

None.

6. Conflict of Interest

None.

References

1. Frymoyer JW, Hadler NM, Kostuik JP. The Adult Spine: Principles and Practice. New York, Raven Press; 1991. p.191
2. Giri J, Uma BG, Pratikshya M, Thomas A, Chaudhary S, Singrapu SK, et al. Sacralization of fifth lumbar vertebra- a case report. *Eur J Biomed Pharm Sci.* 2019;6(1):671-4.
3. Sharma V. A., Sharma D. K., Shukla C. K. Osteogenic study of lumbosacral transitional vertebra in central India region. *J Anat Soc India.* 2011;60(2):212-7. <https://doi.org/10.1016/j.jasi.2016.08.042>
4. Castellvi AE, Goldstein LA, Chan DP. Lumbosacral transitional vertebrae and their relationship with lumbar extradural defects. *Spine J.* 1984;9(5):493-5.
5. Hsieh CY, Vanderford JD, Moreau SR, Prong T. Lumbosacral transitional segments: classification, prevalence, and effect on disk height. *J Manipulative Physiol Ther.* 2000;23(7):483-9.
6. Brailsford JF. Deformities of the lumbosacral region of the spine. *Brit J Surg.* 1929;16(64):562-627. <https://doi.org/10.1002/bjs.1800166405>
7. Bustami F. The anatomical features and functional significance of lumbar transitional vertebra. *Jordan Med J.* 1989;23(1):49-59.
8. Sharma VA, Sharma DK, Baweja SS, Sharma DK. Osteogenic study of lumbosacral transitional vertebra in central India region. *J Anat Soc India.* 2016;65(2):S11. <https://doi.org/10.1016/j.jasi.2016.08.042>
9. Mitchell GA. The significance of lumbosacral transitional vertebrae. *Brit J Surg.* 2005;24(93):147-58. <https://doi.org/10.1002/bjs.1800249320>
10. Erken E, Ozer HT, Gulek B, Durgun B. The association between cervical rib and Sacralization. *Spine.* 2002;27(15):1659-64.
11. Bertolotti M. Contributo alla conoscenza dei vici di differenziazione regionale del rachide con speciale riguardo alla asimilazione sacrale della v. lombare. *Radiologique Medica.* 1917;4:113-44.
12. Krishnamurthy A, Adibatti M. Study on incidence of sacralisation of fifth lumbar vertebra in South Indian population. *Ital J Anat Embryol.* 2016;121(1):60-5.

Cite this article: Gupta K, Choudhary S, Batra APS. Type IIA sacralisation: A case report. *Indian J Clin Anat Physiol.* 2026;13(1):25-26.